

# Does Surgical Removal of the Thymus Have Deleterious Consequences?

Henry J. Kaminski, MD, Linda L. Kusner, PhD, Gary R. Cutter, PhD, Rozen Le Panse, PhD, Cameron D. Wright, MD, Yaron Perry, MD, and Gil I. Wolfe, MD

*Neurology*® 2024;102:e209482. doi:10.1212/WNL.0000000000209482

## Correspondence

Dr. Kaminski

hkaminski@mfa.gwu.edu

## Abstract

The role of immunosenescence, particularly the natural process of thymic involution during aging, is increasingly acknowledged as a factor contributing to the development of autoimmune diseases and cancer. Recently, a concern has been raised about deleterious consequences of the surgical removal of thymic tissue, including for patients who undergo thymectomy for myasthenia gravis (MG) or resection of a thymoma. This review adopts a multidisciplinary approach to scrutinize the evidence concerning the long-term risks of cancer and autoimmunity post-thymectomy. We conclude that for patients with acetylcholine receptor antibody-positive MG and those diagnosed with thymoma, the removal of the thymus offers prominent benefits that well outweigh the potential risks. However, incidental removal of thymic tissue during other thoracic surgeries should be minimized whenever feasible.

The thymus is a primary lymphoid organ that serves as the site of T-cell maturation to assure a robust response toward foreign antigens, while maintaining a tolerance toward self.<sup>1,2</sup> During life, structural changes affect the thymus, such as natural thymic involution related to aging or alterations induced by stress or pathologic conditions.<sup>3-5</sup> Historically, the prevailing belief was that the thymus holds minimal significance in adulthood because of its involution. However, a growing body of evidence challenges this perspective. There are reports that indicate that sustaining thymopoiesis well into adulthood can have significant benefits while its deterioration may elevate the risk of neoplasia and autoimmune disorders.<sup>6,7</sup> Consequently concerns have been raised that surgical removal of the thymus in a variety of clinical scenarios may lead to deleterious consequences.

On the other hand, studies have documented unequivocal benefits of thymus removal in specific cases, such as patients with certain autoimmune forms of myasthenia gravis (MG)<sup>8,9</sup> and individuals diagnosed with thymic neoplasia who require surgery.<sup>10</sup> Nevertheless, the potential negative impact of surgical thymus removal on immune function, potentially leading to increased rates of cancer and autoimmunity, deserves further scrutiny.<sup>11</sup> Here, we briefly review the function of the thymus, assess what is known about adverse effects of thymic resection on immune function, and address the current limitations of our knowledge in guiding clinical decisions concerning thymectomy.

## Thymus Function From Fetus to Old Age

The purpose of the immune system is to protect the host from foreign invasion, whether the threat is extrinsic, such as bacteria, viruses, or fungi, or intrinsic, as in neoplasia. Given the countless antigens a person encounters during a lifetime, the task of ensuring tolerance to self while mounting an effective response to nonself is daunting. T cells are the critical regulator of

From the Department of Neurology & Rehabilitation Medicine (H.J.K.), George Washington University, DC; Department of Pharmacology & Physiology (L.L.K.), and Department of Biostatistics (G.R.C.), University of Alabama at Birmingham; INSERM (R.L.P.), Institute of Myology, Center of Research in Myology, Sorbonne University, Paris, France; Department of Surgery (C.D.W.), Harvard Medical School, Boston, MA; and Department of Surgery (Y.P.), and Department of Neurology (G.I.W.), Jacobs School of Medicine and Biomedical Sciences, University at Buffalo/SUNY, NY.

Go to [Neurology.org/N](https://www.neurology.org/N) for full disclosures. Funding information and disclosures deemed relevant by the authors, if any, are provided at the end of the article.

The Article Processing Charge was funded by NIH.

This is an open access article distributed under the terms of the Creative Commons Attribution-NonCommercial-NoDerivatives License 4.0 (CC BY-NC-ND), which permits downloading and sharing the work provided it is properly cited. The work cannot be changed in any way or used commercially without permission from the journal.

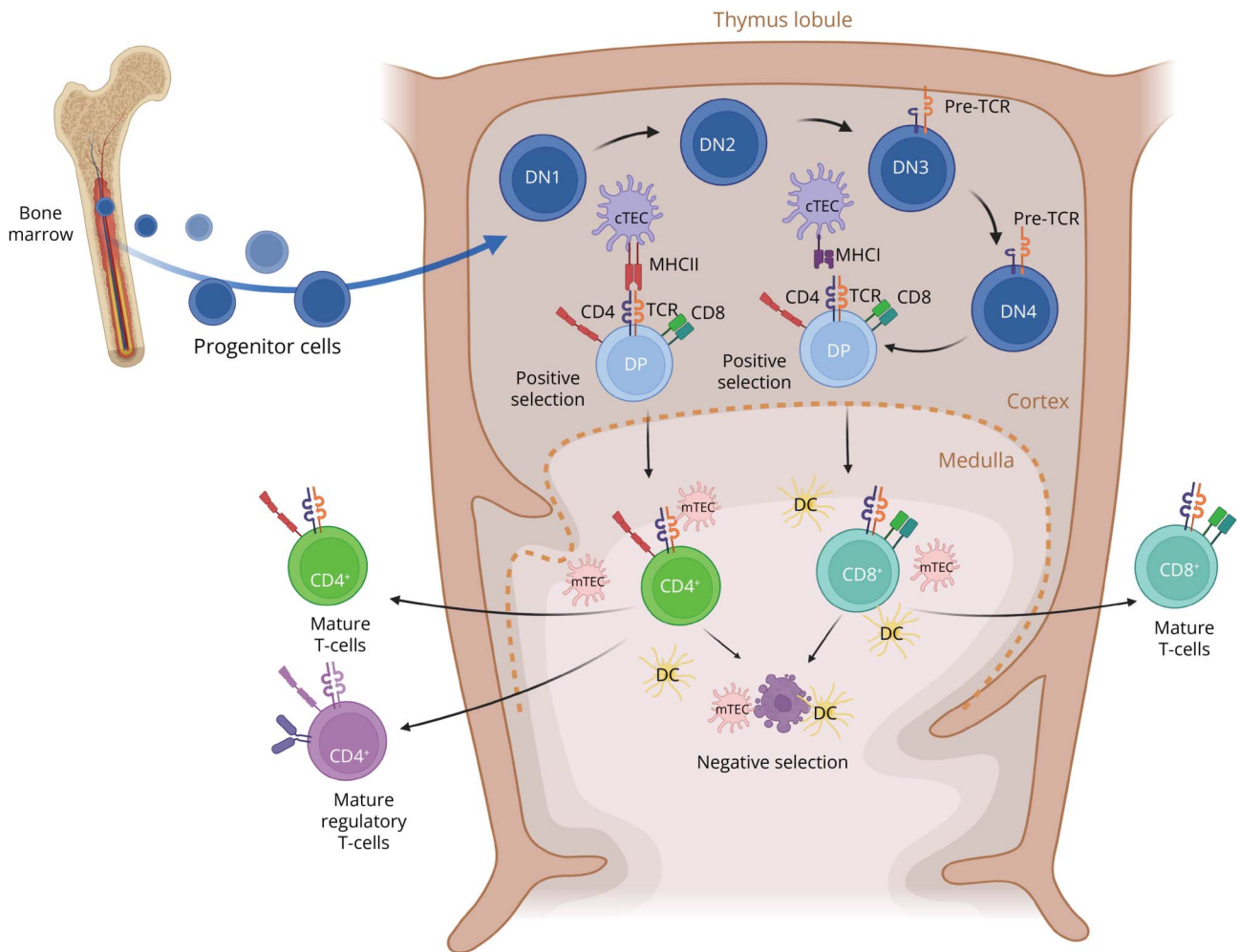
## Glossary

**MG** = myasthenia gravis; **MHC** = major histocompatibility; **MR** = magnetic resonance; **TCR** = T-cell receptor; **TES** = thymic epithelial space; **TREC** = T-cell receptor excision circle.

distinguishing self from foreign invaders. The thymus functions to select T cells based on what is foreign and needs to be eliminated and what is self. Those T cells that react to self-antigens are eliminated, whereas those that recognized non-self-antigens proceed through maturation. The thymus has 2 primary histologic components: the perivascular space and the thymic epithelial space (TES), the latter further subdivided into the cortical and medullary functional areas (Figure 1). The TES is the site of active T-cell development or thymopoiesis.<sup>12</sup>

Progenitor cells from the bone marrow migrate to the thymus entering through the cortical-medullary junction through blood vessels. These progenitors are double-negative cells lacking the coreceptors CD4 and CD8.<sup>1</sup> They become committed to a T-cell lineage through the expression of both CD4 and CD8. These progenitor T cells begin the critical stage of gene rearrangement at the T-cell receptor (TCR) locus to ultimately generate a unique TCR, as well as generating mature, double-positive thymocytes. A double-positive cell

**Figure 1** T-Cell Development in the Thymus



Hematopoietic progenitor cells enter the thymus and migrate to the outer cortex as immature double-negative (DN) thymocytes, lacking both CD4 and CD8 coreceptors. The DN population matures as observed by the CD44 and CD25 expression: CD44<sup>+</sup>CD25<sup>-</sup> (DN1), CD44<sup>+</sup>CD25<sup>+</sup> (DN2), CD44<sup>-</sup>CD25<sup>+</sup> (DN3), and CD44<sup>-</sup>CD25<sup>-</sup> (DN4). During this time, the DN thymocytes also express the pre-TCR consisting of a TCR β-chain and an invariant preTCR α-chain (pTα) allowing the TCRβ gene rearrangements. Expression of the preTCR enables DN cells with productive TCRβ rearrangements to differentiate into CD4<sup>+</sup>CD8<sup>+</sup> double-positive (DP) thymocytes and the rearrangement of the TCR α-chain to begin. Positive selection through the interaction with the MHCI and MHCII on the cortical thymic epithelial cells (cTECs) determines the fate of the thymocyte during TCRβ and TCR α gene rearrangements. The thymocytes travel to the medulla as single-positive CD4<sup>+</sup> or CD8<sup>+</sup> to undergo central tolerance through negative selection by interacting with the dendritic cells, medullary thymic epithelial cells (mTECs) and B cells. The recognition of self will direct the cell to an apoptotic pathway or a regulatory T-cell fate. Mature CD4<sup>+</sup> and CD8<sup>+</sup> thymocytes can then exit the thymus and begin their role in immune regulation.

interacts with cortical thymic epithelial cells, which express major histocompatibility (MHC) complexes. This positive selection process identifies T cells that will interact with antigens in context of the MHC of the individual. If this interaction does not occur, the cell dies within 3–5 days, a so-called death by neglect, thereby eliminating T cells that would not interact with MHC.<sup>13</sup> The TCR recognition of MHC class II drives the double-positive T cells to a CD4 fate, whereas the fate of CD8 single-positive naïve T cells is reliant on MHC class I signaling to the TCR.<sup>1</sup> T cells that recognize self with high affinity are eliminated through negative selection dependent on self-antigens expressed by medullary thymic epithelial cells. Mature single positive CD4 or CD8 T cells then exit to the periphery as T helper or cytotoxic T cells, establishing a robust repertoire of T cells with diverse TCRs for host protection.

The human thymus begins to involute from the time of birth, most likely as a normal process during general maturation; however, the process is accelerated because of oxidative damage by reactive oxygen species with further aging.<sup>3,14</sup> The thymus slowly undergoes involution through a person's life, coinciding with other aspects of the immune system. The involution is seen as a rapid and irreversible component of aging or response to stress. The thymus undergoes structural changes, with a decrease in the number of functional thymic epithelial cells and a shift toward more fatty tissue.<sup>4</sup> The stromal cells in the medullary region of the thymus demonstrate a decrease in tissue restricted antigen expression suggesting that the maturation of naïve T cells declines, potentially placing the host at risk for self-reactivity.<sup>5</sup> The peripheral T-cell repertoire becomes less diverse. This phenomenon of thymic involution, coupled with the broader concept of immune senescence, is shared among vertebrates. The decline most likely contributes to increased susceptibility to infections, cancer, and autoimmune diseases as well as a reduced response to vaccination as people age.<sup>15</sup> Whether this natural decline in immunity serves an evolutionary advantage or is a result of mechanisms supporting robust immune responses in early life but not later in life is an open question.<sup>5,16</sup> Enhancing immune function in the elderly is an active area of therapeutic development.<sup>17–19</sup>

## Diseases Association With Thymic Pathology

In addition to natural age-related involution, thymic changes can be observed in different situations. During pregnancy, acute thymic involution due to hormonal changes is observed which may contribute to maternal–fetal tolerance.<sup>20</sup> Stress, pathogen infection, and even drugs can also trigger acute thymic involution associated with the induction of thymocyte apoptosis. These involutions are transient, and the thymus recovers rapidly.<sup>21</sup> In elderly individuals, thymic involution is associated with immunosenescence and an increase in proinflammatory cytokines (inflammaging), which can affect

T-cell development and explain the increased incidence of autoimmunity.<sup>18</sup>

Thymic hyperplasia is characterized by an increase in the size and weight of the thymus, defined as true thymic hyperplasia, and at times is observed as a rebound phenomenon in patients recovering from acute thymic atrophy.<sup>21</sup> By contrast, lymphofollicular hyperplasia is associated with ectopic germinal centers, often but not necessarily associated with true thymic hyperplasia. Thymic hyperplasia can be associated with specific diseases, such as thymomas or MG,<sup>22</sup> as described below. Thymic hyperplasia may also be observed in other autoimmune diseases, such as Grave disease and Sjögren syndrome but the link with the pathology is not clearly established.<sup>23,24</sup>

Thymomas are neoplasms originating from thymic epithelial cells and represent one of the most prevalent types of adult tumors located in the anterior mediastinum. The histologic classification established by the World Health Organization includes type A, B1, B2, B3, and AB thymomas. Type A was classified as medullary thymomas, types B1 and B2 as cortical thymomas, type AB as mixed thymomas (involving both cortical and medullary epithelial cells), and type B3 as atypical thymomas. Thymoma is associated with several paraneoplastic syndromes, with MG being the most common, mainly linked to B1 and B2 thymoma types. In addition, other diseases may be observed in concert with thymoma, including systemic lupus erythematosus, rheumatoid arthritis, neuro-myotonia, vitiligo, or pemphigus.<sup>25</sup> The incidence of MG in patients with thymoma is approximately 30%, although this rate exhibits considerable variability across studies.<sup>26,27</sup>

MG with autoantibodies targeting nicotinic acetylcholine receptors at the neuromuscular junction is frequently associated with thymic abnormalities. The thymus can be considered as the effector organ. Thymic changes are clearly observed in the early-onset form of the disease and less often in late-onset MG (above the age of 50) as the thymus naturally involutes.<sup>28</sup> In MG, the thymus is characterized by B-cell infiltration, and 50%–60% of specimens display lymphofollicular hyperplasia defined by the development of ectopic germinal centers in the thymic medulla.<sup>29,30</sup> Germinal centers are structures usually found in secondary organs and are responsible for the proliferation, differentiation, and generation of memory B cells and plasma cells. In MG, the degree of lymphofollicular hyperplasia correlates with acetylcholine receptor antibody levels,<sup>28,31</sup> but not clinical disease severity.<sup>32</sup> In parallel to thymic germinal center development, neoangiogenesis is also observed with a large number of endothelial venules surrounding germinal centers and lymphatic vessels.<sup>33</sup> These vessels promote peripheral cell infiltration through the expression of diverse chemokines.<sup>34</sup> In early-onset MG, the thymus is highly inflammatory, and this affects the development of T cells inducing an imbalance between regulatory T cells and pathogenic Th17 cells.<sup>35,36</sup> For decades, thymectomy has been performed as a treatment for patients with MG.<sup>37</sup> More recently, a randomized controlled trial of

thymectomy in adult patients with acetylcholine receptor antibody-positive MG demonstrated clinical improvement at 3 and 5 years.<sup>38</sup> The beneficial effect likely relates to removal of autoreactive T cells and reduced cytokine secretion, memory B cells, and plasma cells by resection of the inflammatory thymus.

## Thymectomy as Therapy

In the late 19th century, thymic pathology in patients with MG was first appreciated.<sup>39</sup> Sauerbruch performed a thymectomy for treatment of a young woman with severe hyperthyroidism, who also had MG, noting an improvement in MG-related weakness. Blalock was the first to perform thymectomy specifically for treatment of MG, first in the setting of thymic tumor and then in patients without neoplasia.<sup>37,40,41</sup> Keynes<sup>42</sup> provided support for performing thymectomy in a large series of MG patients without thymoma. Subsequent studies with long-term follow-up confirmed favorable outcomes after thymectomy for patients with MG,<sup>43,44</sup> including children.<sup>45</sup> Nonetheless, some studies casted doubt on its effectiveness, revealing significant variations in methodological rigor, follow-up durations, and criteria of improvement. A 1990 survey of experts in MG care demonstrated wide variation of referral for thymectomy with some experts never recommending surgery.<sup>46</sup> In 2000, a practice parameter of the American Academy of Neurology concluded that all published studies had serious flaws, but removal of the thymus could be recommended as an *option* for treatment of patients without thymoma.<sup>47</sup> There was no comment on autoantibody status, disease severity, age, or sex as factors for selection of patients.

The practice parameter did stimulate an international consortium of neurologists, thoracic surgeons, pathologists, and scientists to organize a randomized phase 3 trial of thymectomy plus prednisone vs prednisone alone. In 2016, the results of the study were published, and thymectomy with prednisone was demonstrated to be beneficial for patients with acetylcholine receptor antibody-positive generalized MG.<sup>8</sup> The new data led the American Academy of Neurology to revise their practice parameter to recommend that neurologists advise patients with acetylcholine receptor antibody-positive generalized MG to consider thymectomy but to balance the benefit with the discomfort and costs of surgery.<sup>48</sup> Several national and international consensus treatment guidelines recommend thymectomy for patients younger than 50 years with acetylcholine receptor antibodies.<sup>9,49,50</sup>

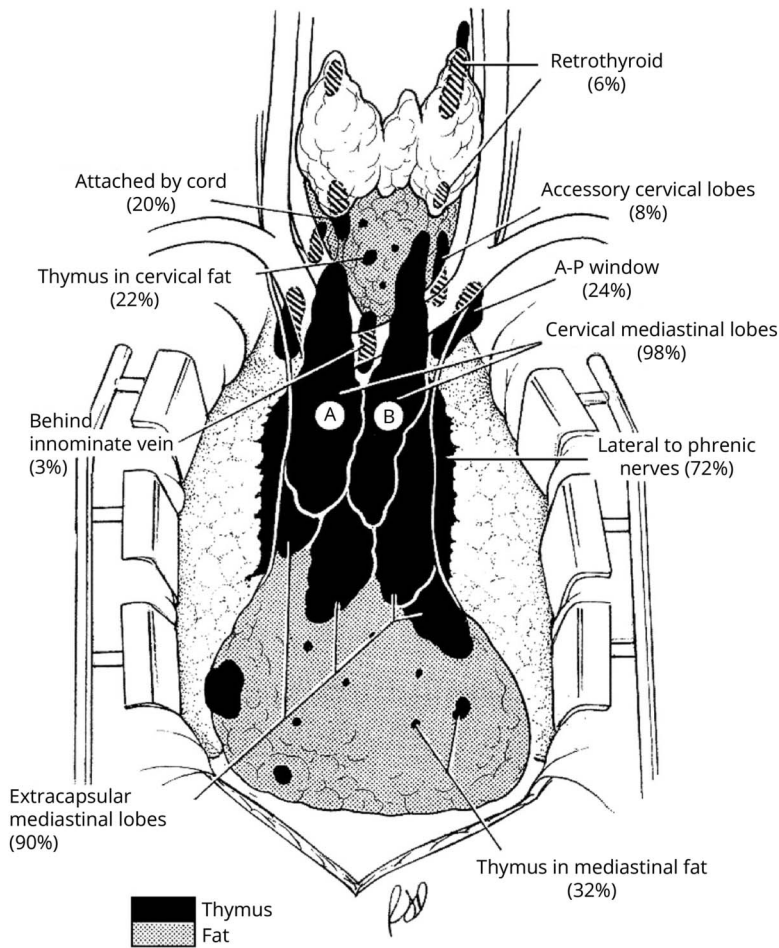
For thymomas, regardless of a relationship to autoimmune disease, the National Comprehensive Cancer Network (NCCN) guidelines indicate resection as the standard of care.<sup>51</sup> Rare patients with significant comorbidities including advanced age may not benefit from surgical removal of the tumor, especially when the growth rate of the tumor is not expected to impact life expectancy or the complexity of surgical removal poses a high likelihood of complications.

In a general way, there are 2 types of thymectomy—standard in which the gland is removed within the confines of an often ill-defined capsule—and radical (extended) thymectomy in which the majority of anterior mediastinal fatty tissue is removed from phrenic nerve to phrenic nerve and from the diaphragm to the thyroid (Figure 2).<sup>52</sup> Comparative efficacy of these 2 types of resection for MG is an area of controversy. Several reports indicate there are relatively widespread rests of thymic cells in the fatty tissue of the anterior mediastinum and lower neck (Figure 2).<sup>53</sup> The 2016 randomized trial used a trans-sternal extended thymectomy for the surgical resection with the thought that it would offer the maximal benefit. The trial was organized and initiated at a time before wide acceptance of less invasive procedures. Most thymectomies are now done by a minimally invasive approach, either video-assisted or robot-assisted. Although rests of thymic cells have been noted in the mediastinal fat separate from the thymus gland proper, there is a paucity of good evidence that removal of this additional fat dramatically improves outcomes of MG after thymectomy. A pathologic study examined the number of germinal centers in patients with MG who had an extended thymectomy and found no germinal centers in the pericardial fat.<sup>53</sup> Another study indicated there were widespread thymic rests that were not surgically accessible and are thus left behind, even after an extended thymectomy.<sup>54</sup> It is unknown as to whether these thymic rests have any active immunologic function. The same uncertainty exists to a degree regarding resection of thymomas; many surgeons resect just the thymoma while others resect the adjacent thymus and mediastinal fat along with the tumor. Questions remain as to whether the additional resection of fat and thymus is necessary or improves recurrence rates. A recent meta-analysis in thymoma compared restricted thymoma removal with complete thymectomy with thymomectomy and reported no difference in recurrence or thymoma-related deaths.<sup>55</sup> Pathology reports are difficult to interpret after thymoma resections and typically do not definitely state whether all surrounding normal thymus has been resected. Patients after thymoma resection may have some or all of their normal thymus remaining. Careful reading of the operative note in conjunction with review of the preoperative imaging and the pathology report can lead to a reasonable degree of certainty as to the completeness of any thymectomy.

In addition to thymic resections for MG and thymoma, the gland may be removed as part of other surgeries. The thymus is removed incidentally during cardiac surgery in neonates and infants as the normally large infant thymus can block the operative field and access to the aorta. Most surgeons remove both lobes of the thymus in such cases. In adult cardiac surgery some thymus may be removed but it is very uncommon that a total thymectomy is done. In about 2 percent of cases, parathyroid adenomas are located in the superior mediastinum within the thymus as a result of the embryologic development of the parathyroid gland. Usually parathyroid adenomas can be accessed and removed with a cervical approach from the neck. In such cases only a small portion of the



**Figure 2** Surgical Anatomy of the Thymus



The illustration depicts the anatomy of the thymus. A and B designate the classic depiction of the thymus with majority of thymus in the cervical mediastinum. However, thymic tissue is frequently found outside these areas extending to the neck and the mediastinum. The black identifies thymus tissue and gray is fat, which may have small amounts of thymic tissue or only microscopic thymus. The percentages estimate the percentage of thymus and fat. Used with permission of Wolters Kluwer Health, Inc. published Jaretzki et al.<sup>52</sup>

unilateral superior thymus is removed. In rare instances a total thymectomy is done to remove a parathyroid adenoma.<sup>56</sup>

Up until recently thymectomy was performed for enlarged thymic glands thought to represent thymic tumor but in reality were simply thymic hyperplasia.<sup>57,58</sup> Thymic hyperplasia can be PET avid, which had previously increased the concern for a thymic tumor. However, with more widespread use of magnetic resonance (MR) and increased training of the radiology community, a reliable diagnosis of thymic hyperplasia can be made and thymectomy avoided. On CT, thymic hyperplasia is in a midline location and has a bipyramidal shape often with intercalated fat.<sup>59</sup> Chemical shift MR can be used to detect microscopic fat which is highly suggestive of thymic hyperplasia.<sup>60</sup> In addition, in the past, thymectomy was done for small thymic lesions thought to be thymomas, but which turned out to be benign thymic cysts. CT may not properly identify the nature of small rounded thymic lesions that have density higher than water, which suggest a possible thymoma. However, many thymic cysts exhibit greater density than expected because of microscopic bleeding. On the other hand, MR is

extremely helpful in making a firm diagnosis of a thymic cyst, which exhibits thin smooth walls with no nodularity or septations.<sup>e1</sup>

## Does Surgical Removal of the Thymus Have Deleterious Consequences?

Surgical removal of the thymus has generally been considered to have minimal consequence. Investigations of children and adults who underwent removal of thymus during cardiac surgery for congenital heart defects have not demonstrated deleterious clinical impacts.<sup>e2-e5</sup> This is particularly surprising because one would expect thymectomy in early life to have the most significant impact. Despite the lack of adverse effects, the number of circulatory T cells after thymectomy is consistently found to be reduced, and T-cell receptor excision circles (TREC), which assess production of new T cells and measure thymus preservation, also decrease in number.<sup>e6</sup> Interestingly, individuals who have undergone partial thymectomy show an increase in TREC in the months after the operation.<sup>e7</sup>

It is important to note that thymectomy would not have any effect on the established peripheral T-cell repertoire.

Recently, a report published in the *New England Journal of Medicine* raised concern about the deleterious consequences of thymectomy in adults.<sup>11</sup> In this retrospective observational study of 1,146 patients who underwent thymus removal and had a matched control that had undergone cardiothoracic surgery without thymectomy, patients who had their thymus removed were at increased risk of all-cause mortality, cancer, and autoimmune disease. The risk of death and development of a variety of cancers in the first 5 years after surgical thymus removal was 2-fold the rate in controls, with a lesser increased risk extending over a period of 20 years. The increased risk of postoperative autoimmune disease was observed at 5 years after excluding patients with preoperative infection, cancer, and autoimmune disorders, but did not persist. As expected from previous studies,<sup>6</sup> Kooshesh et al.<sup>11</sup> did observe reduced TRECs vs controls, but this was only assessed in a much smaller subgroup (22 thymectomy patients; 19 controls). Proinflammatory cytokines measured in plasma were higher in these patients. However, the timing of the sampling for these assays in relationship to surgery is not specified, which could influence the interpretation of results.

The study raised concern among health care providers and patients about the routine removal of the thymus during cardiothoracic procedures. This concern has been extended to neuromuscular neurologists who recommend thymectomy in the management of MG. The apprehension does not center on patients with thymomatous MG; indeed cancerous or suspected thymic mass was the indication for thymectomy in 871 of the 1,146 cases surveyed.<sup>11</sup> Given the prominence of the journal and the supportive, noncritical nature of the accompanying editorial,<sup>8</sup> the conclusions of the study may dissuade physicians and the majority of patients with generalized MG who are nonthymomatous from considering a safe procedure<sup>9</sup> that yields clear long-term benefits extending to at least 5 years in a randomized, controlled extension study.<sup>8,38</sup>

Several methodological issues with the study by Kooshesh et al.<sup>11</sup> bear consideration. The large number of cancerous or suspected thymic masses in the thymectomy group raises the question of whether the increased relative risks of death or subsequent cancer relate more to a thymic irregularity, itself, or to the gland's removal. The appropriateness of a matched control group undergoing more routine cardiac surgery can also be questioned in this context. Related to this point, per Table S1 of the study by Kooshesh et al.,<sup>11</sup> only 265 thymectomy patients had parathyroid or thyroid excisions, cardiac surgery, or indeterminate indications for thymectomy. In such cases, a complete resection of the multicentric thymus gland is generally not performed. Cervical extensions of the gland are typically not removed during cardiac surgery.

In contrast to the findings in the study by Kooshesh et al.<sup>11</sup> previous studies in patients with MG have not observed

increased health risks from thymectomy. One investigation found no increase in cancer after thymectomy,<sup>e10</sup> whereas another study found the risk of extrathymic tumors in patients with MG who had undergone thymectomy was no higher than that in the general population after the second postoperative year.<sup>e11</sup> A potential protective effect of MG in the development of extrathymic tumors has also been observed.<sup>e12</sup> Similarly, a signal of increased malignancy rates has not been observed in the Society of Thoracic Surgeons Congenital Heart Surgery Database, the largest database in North America of congenital cardiac malformations containing 600,000 congenital heart surgery procedure records from more than 1,000 participating physicians.<sup>e13</sup>

The increased risk of mortality observed by Kooshesh et al.<sup>11</sup> occurred very early after surgery, potentially due to selection bias among the 2 studied populations. The survival curves remain almost parallel beyond the first year. Therefore, the risk could rationally be attributed more to direct innate risks of undergoing surgery. Furthermore, the investigators did not specify in the patient matching process whether the type and date of surgery were taken into account. The thymectomized group included patients from 1993 to 2020 while the control group included patients from 2000 to 2019. Surgical procedures and postoperative care may have differed, particularly for the thymectomy group in that first decade of the time period.

For the risk of autoimmunity, there was no significant difference and the authors simply mention "thymectomy appeared to have transiently and modestly increased the risk of autoimmune disease." In Figure S9 of Kooshesh et al.,<sup>11</sup> in the group without prior autoimmunity, 16 percent developed MG but no mention of thymoma is made. Because MG is a rare disease, the quoted percentage is extremely high, which suggests that there was already a bias in favor of autoimmunity despite excluding patients with clinical symptoms of such. Table S9 shows a difference in the male/female ratios, with significantly more women in the thymectomy group, which is a subgroup generally at higher risk to develop autoimmunity in the first place. In addition, the average age of controls in years at the time of assessment was 78 and 65 at the time of surgery; for the thymectomy group the age at evaluation was 68 years and 50 years at the time of surgery. While there was an attempt to have matched cohorts, and the mean ages seem to match, the analyses do not appear to adjust for covariate imbalances given the use of a log-rank test on the survival curves. This may confound the censoring patterns of follow-up of the participants, possibly eliminating earlier deaths from the control group. Among the subgroups there are large differences in gender, assessment age and age at surgery, so the mean values may not reflect the adequacy of the matches for the questions being asked.

Finally, data from the biological assays need to be viewed with caution. Granted, immune analyses showed differences in the

thymectomy group vs matched controls, but this was observed in a small subpopulation, under 2%, of the entire study group. Furthermore, the implications of such changes remain uncertain. Naïve T-cell populations are long-lived,<sup>e14</sup> so the premise that postthymectomy changes in lymphocyte populations would lead to a near immediate impact on death rates seems implausible.

## Conclusion

In summary, there remains much to learn about the impact of immunosenescence on development of systemic inflammation, autoimmune diseases, and cancer. The future development of therapies that allow return of immune function to a more youthful time in a person's life is an important area of investigation, especially given the aging population in many countries.<sup>e15</sup> Understanding that the thymus may play an immunologic role throughout life, it seems only prudent that “unnecessary” thymectomy in the setting of cardiac surgery, thymic hyperplasia or benign cysts be avoided. However, the benefit of thymectomy in thymic tumors and to reduce disability of MG reinforces the established position of thymic resection among the community of thoracic surgeons and neurologists caring for these patients and their families. Similar to other “gray areas” of medicine, a greater understanding of the physiology of aging and the true impacts of intervention should lead to refinement of therapeutic approaches.

## Acknowledgment

We dedicate this work to the late Dr. Alfred Jaretzki for his inspiration as a physician and person.

## Study Funding

The authors report no targeted funding.

## Disclosures

H.J. Kaminski is principal investigator for the Rare Disease Network (MGNet supported by NIH grant U54NS115054) is a consultant for R43NS12432, Roche, Takeda, Cabaletta Bio, UCB Pharmaceuticals, Canopy EMD Serono, Ono Pharmaceuticals, ECoR1, Gilde Healthcare, and Admirix, Inc., has received research support from Argenix (paid to institution), and has equity interest in Mimivax, LLC, and has equity interest in Mimivax, LLC, and serves as a consultant for GRO Biotechnology, CSL Berhing, Amplo Biotechnology, and Sanofi. G.I. Wolfe has served as vice chair for the International Treatment Consensus panel (funded by the Myasthenia Gravis Foundation of America). The other authors report no relevant disclosures. Go to [Neurology.org/N](https://www.neurology.org/N) for full disclosures.

## Publication History

Received by *Neurology* January 18, 2024. Accepted in final form March 28, 2024. Submitted and externally peer reviewed. The handling editor was Associate Editor Brian C. Callaghan, MD, MS, FAAN.

## Appendix Authors

Name	Location	Contribution
<b>Henry J. Kaminski, MD</b>	Department of Neurology & Rehabilitation Medicine, George Washington University, DC	Drafting/revision of the manuscript for content, including medical writing for content; study concept or design
<b>Linda L. Kusner, PhD</b>	Department of Pharmacology & Physiology, University of Alabama at Birmingham	Drafting/revision of the manuscript for content, including medical writing for content; study concept or design
<b>Gary R. Cutter, PhD</b>	Department of Pharmacology & Physiology, University of Alabama at Birmingham	Drafting/revision of the manuscript for content, including medical writing for content; study concept or design
<b>Rozen Le Panse, PhD</b>	INSERM, Institute of Myology, Center of Research in Myology, Sorbonne University, Paris, France	Drafting/revision of the manuscript for content, including medical writing for content; study concept or design
<b>Cameron D. Wright, MD</b>	Department of Surgery, Harvard Medical School, Boston, MA	Drafting/revision of the manuscript for content, including medical writing for content; study concept or design
<b>Yaron Perry, MD</b>	Department of Surgery, Jacobs School of Medicine and Biomedical Sciences, University at Buffalo/SUNY, NY	Drafting/revision of the manuscript for content, including medical writing for content; study concept or design
<b>Gil I. Wolfe, MD</b>	Department of Neurology, Jacobs School of Medicine and Biomedical Sciences, University at Buffalo/SUNY, NY	Drafting/revision of the manuscript for content, including medical writing for content; study concept or design

## References

- Ashby KM, Hogquist KA. A guide to thymic selection of T cells. *Nat Rev Immunol*. 2024;24(2):103-117. doi:10.1038/s41577-023-00911-8
- This S, Rogers D, Mallet Gauthier E, Mandl JN, Melichar HJ. What's self got to do with it: sources of heterogeneity among naive T cells. *Semin Immunol*. 2023;65:101702. doi:10.1016/j.smim.2022.101702
- Lynch HE, Goldberg GL, Chidgey A, Van den Brink MR, Boyd R, Sempowski GD. Thymic involution and immune reconstitution. *Trends Immunol*. 2009;30(7):366-373. doi:10.1016/j.it.2009.04.003
- Steinmann GG, Klaus B, Muller-Hermelink HK. The involution of the ageing human thymic epithelium is independent of puberty. A morphometric study. *Scand J Immunol*. 1985;22(5):563-575. doi:10.1111/j.1365-3083.1985.tb01916.x
- Griffith AV, Fallahi M, Venables T, Petrie HT. Persistent degenerative changes in thymic organ function revealed by an inducible model of organ regrowth. *Aging Cell*. 2012;11(1):169-177. doi:10.1111/j.1474-9726.2011.00773.x
- White MC, Holman DM, Boehm JE, Peipins LA, Grossman M, Henley SJ. Age and cancer risk: a potentially modifiable relationship. *Am J Prev Med*. 2014;46(3 suppl 1):S7-S15. doi:10.1016/j.amepre.2013.10.029
- Goronzy JJ, Weyand CM. Immune aging and autoimmunity. *Cell Mol Life Sci*. 2012;69(10):1615-1623. doi:10.1007/s0018-012-0970-0
- Wolfe GI, Kaminski HJ, Aban IB, et al. Randomized trial of thymectomy in myasthenia gravis. *N Engl J Med*. 2016;375(6):511-522. doi:10.1056/NEJMoa1602489
- Narayanawami P, Sanders DB, Wolfe G, et al. International consensus guidance for management of myasthenia gravis: 2020 update. *Neurology*. 2021;96(3):114-122. doi:10.1212/WNL.00000000000011124
- Falkson CB, Vella ET, Ellis PM, Maziak DE, Ung YC, Yu E. Surgical, radiation, and systemic treatments of patients with thymic epithelial tumors: a systematic review. *J Thorac Oncol*. 2023;18(3):299-312. doi:10.1016/j.jtho.2022.10.016
- Kooshesh KA, Foy BH, Sykes DB, Gustafsson K, Scadden DT. Health consequences of thymus removal in adults. *N Engl J Med*. 2023;389(5):406-417. doi:10.1056/NEJMoa2302892
- Adu-Berchie K, Obuseh FO, Mooney DJ. T cell development and function. *Regeneration Res*. 2023;26(4):126-138. doi:10.1089/rej.2023.0015



13. Starr TK, Jameson SC, Hogquist KA. Positive and negative selection of T cells. *Annu Rev Immunol*. 2003;21:139-176. doi:10.1146/annurev.immunol.21.120601.141107
14. Griffith AV, Venables T, Shi J, et al. Metabolic damage and premature thymus aging caused by stromal catalase deficiency. *Cell Rep*. 2015;12(7):1071-1079. doi:10.1016/j.celrep.2015.07.008
15. Palmer S, Albergante L, Blackburn CC, Newman TJ. Thymic involution and rising disease incidence with age. *Proc Natl Acad Sci USA*. 2018;115(8):1883-1888. doi:10.1073/pnas.1714478115
16. Shanley DP, Aw D, Manley NR, Palmer DB. An evolutionary perspective on the mechanisms of immunosenescence. *Trends Immunol*. 2009;30(7):374-381. doi:10.1016/j.it.2009.05.001
17. Salminen A. Immunosuppressive network promotes immunosenescence associated with aging and chronic inflammatory conditions. *J Mol Med (Berl)*. 2021;99(11):1553-1569. doi:10.1007/s00109-021-02123-w
18. Thomas R, Wang W, Su DM. Contributions of age-related thymic involution to immunosenescence and inflammaging. *Immun Ageing*. 2020;17:2. doi:10.1186/s12979-020-0173-8
19. Cunha LL, Perazzo SF, Azzi J, Cravedi P, Riella LV. Remodeling of the immune response with aging: immunosenescence and its potential impact on COVID-19 immune response. *Front Immunol*. 2020;11:1748. doi:10.3389/fimmu.2020.01748
20. Paolino M, Kogalgruber R, Cronin SJF, et al. RANK links thymic regulatory T cells to fetal loss and gestational diabetes in pregnancy. *Nature*. 2021;589(7842):442-447. doi:10.1038/s41586-020-03071-0
21. Ansari AR, Liu H. Acute thymic involution and mechanisms for recovery. *Arch Immunol Ther Exp (Warsz)*. 2017;65(5):401-420. doi:10.1007/s00005-017-0462-x
22. Berrih-Aknin S, Le Panse R. Myasthenia gravis: a comprehensive review of immune dysregulation and etiological mechanisms. *J Autoimmun*. 2014;52:90-100. doi:10.1016/j.jaut.2013.12.011
23. Haider U, Richards P, Gianoukakis AG. Thymic hyperplasia associated with Graves' disease: pathophysiology and proposed management algorithm. *Thyroid*. 2017;27(8):994-1000. doi:10.1089/thy.2017.0086
24. Minato H, Kinoshita E, Nakada S, et al. Thymic lymphoid hyperplasia with multilocular thymic cysts diagnosed before the Sjogren syndrome diagnosis. *Diagn Pathol*. 2015;10:103. doi:10.1186/s13000-015-0332-y
25. Shelly S, Agmon-Levin N, Altman A, Shoenfeld Y. Thymoma and autoimmunity. *Cell Mol Immunol*. 2011;8(3):199-202. doi:10.1038/cmi.2010.74
26. Nakajima J, Murakawa T, Fukami T, Sano A, Takamoto S, Ohtsu H. Post-thymectomy myasthenia gravis: relationship with thymoma and antiacetylcholine receptor antibody. *Ann Thorac Surg*. 2008;86(3):941-945. doi:10.1016/j.athoracsurg.2008.04.070
27. Regnard JF, Magdeleinat P, Dromer C, et al. Prognostic factors and long-term results after thymoma resection: a series of 307 patients. *J Thorac Cardiovasc Surg*. 1996;112(2):376-384. doi:10.1016/S0022-5223(96)70265-9
28. Truffault F, de Montpreville V, Eymard B, Sharshar T, Le Panse R, Berrih-Aknin S. Thymic germinal centers and corticosteroids in myasthenia gravis: an immunopathological study in 1035 cases and a critical review. *Clin Rev Allergy Immunol*. 2017;52(1):108-124. doi:10.1007/s12016-016-8558-3
29. Bofil M, Janossy G, Willcox N, Chilosi M, Trejdosiewicz LK, Newsom-Davis J. Microenvironments in the normal thymus and the thymus in myasthenia gravis. *Am J Pathol*. 1985;119(3):462-473.
30. Sims GP, Shiono H, Willcox N, Stott DI. Somatic hypermutation and selection of B cells in thymic germinal centers responding to acetylcholine receptor in myasthenia gravis. *J Immunol*. 2001;167(4):1935-1944. doi:10.4049/jimmunol.167.4.1935
31. Berrih-Aknin S, Morel E, Raimond F, et al. The role of the thymus in myasthenia gravis: immunohistological and immunological studies in 115 cases. *Ann NY Acad Sci*. 1987;505:50-70. doi:10.1111/j.1749-6632.1987.tb51282.x
32. Weis CA, Aban IB, Cutter G, et al. Histopathology of thymectomy specimens from the MGTX-trial: entropy analysis as strategy to quantify spatial heterogeneity of lymphoid follicle and fat distribution. *PLoS One*. 2018;13(6):e0197435. doi:10.1371/journal.pone.0197435
33. Weiss JM, Cufi P, Bismuth J, et al. SDF-1/CXCL12 recruits B cells and antigen-presenting cells to the thymus of autoimmune myasthenia gravis patients. *Immunobiology*. 2013;218(3):373-381. doi:10.1016/j.imbio.2012.05.006
34. Cron MA, Maillard S, Villegas J, et al. Thymus involvement in early-onset myasthenia gravis. *Ann NY Acad Sci*. 2018;1412(1):137-145. doi:10.1111/nyas.13519
35. Villegas JA, Bayer AC, Ider K, et al. IL-23/Th17 cell pathway: a promising target to alleviate thymic inflammation maintenance in myasthenia gravis. *J Autoimmun*. 2019;98:59-73. doi:10.1016/j.jaut.2018.11.005
36. Truffault F, Nazzari D, Verdier J, et al. Comparative analysis of thymic and blood Treg in myasthenia gravis: thymic epithelial cells contribute to thymic immunoregulatory defects. *Front Immunol*. 2020;11:782. doi:10.3389/fimmu.2020.00782
37. Blalock A. Thymectomy in treatment of myasthenia gravis. *J Thorac Surg*. 1944;13(4):316-339. doi:10.1016/s0096-5588(20)31647-0
38. Wolfe GI, Kaminski HJ, Aban IB, et al. Long-term effect of thymectomy plus prednisone versus prednisone alone in patients with non-thymomatous myasthenia gravis: 2-year extension of the MGTX randomised trial. *Lancet Neurol*. 2019;18(3):259-268. doi:10.1016/S1474-4422(18)30392-2
39. Hughes T. The early history of myasthenia gravis. *Neuromuscul Disord*. 2005;15(12):878-886. doi:10.1016/j.nmd.2005.08.007
40. Blalock A, Mason MF, Morgan HJ, Riven SS. Myasthenia gravis and tumors of the thymic region. Report of a case in which the tumor was removed. *Ann Surg*. 1939;110(4):544-561. doi:10.1097/0000658-193910000-00005
41. Blalock A, Harvey AM, Ford FR, Lilienthal JL. The treatment of myasthenia gravis by removal of the thymus gland: preliminary report. *JAMA*. 1941;117(18):1529. doi:10.1001/jama.1941.02820440037009
42. Keynes G. The results of thymectomy for myasthenia gravis. *Br Med J*. 1949;1:611-616.
43. Eaton LM, Clagett OT, Bastron JA. The thymus and its relationship to diseases of the nervous system: study of 374 cases of myasthenia gravis and comparison of 87 patients undergoing thymectomy with 225 controls. *Res Publ Assoc Res Nerv Ment Dis*. 1953;32:107-124.
44. Buckingham JM, Howard FM Jr, Bernatz PE, et al. The value of thymectomy in myasthenia gravis: a computer-assisted matched study. *Ann Surg*. 1976;184(4):453-458. doi:10.1097/0000658-197610000-00008
45. Rodriguez M, Gomez MR, Howard FM Jr, Taylor WF. Myasthenia gravis in children: long-term follow-up. *Ann Neurol*. 1983;13(5):504-510. doi:10.1002/ana.410130506
46. Lanska DJ. Indications for thymectomy in myasthenia gravis. *Neurology*. 1990;40(12):1828-1829. doi:10.1212/wnl.40.12.1828
47. Gronseth GS, Barohn RJ. Practice parameter: thymectomy for autoimmune myasthenia gravis (an evidence-based review): report of the Quality Standards Subcommittee of the American Academy of Neurology. *Neurology*. 2000;55(1):7-15. doi:10.1212/wnl.55.1.7
48. Gronseth GS, Barohn R, Narayanaswami P. Practice advisory: thymectomy for myasthenia gravis (practice parameter update): report of the Guideline Development, Dissemination, and Implementation Subcommittee of the American Academy of Neurology. *Neurology*. 2020;94(16):705-709. doi:10.1212/WNL.00000000000009294
49. Murai H, Utsugisawa K, Motomura M, Imai T, Uzawa A, Suzuki S. The Japanese clinical guidelines 2022 for myasthenia gravis and Lambert-Eaton myasthenic syndrome. *Clin Exp Neuroimmunol*. 2023;14(1):19-27. doi:10.1111/cen.3.12739
50. Sussman J, Farrugia ME, Maddison P, Hill M, Leite MJ, Hilton-Jones D. The Association of British Neurologists' myasthenia gravis guidelines. *Ann NY Acad Sci*. 2018;1412(1):166-169. doi:10.1111/nyas.13503
51. NCCN guidelines thymomas and thymic carcinomas [online]. Accessed January 1, 2024. [nccn.org/professionals/physician\\_gls/pdf/thymic.pdf](https://www.nccn.org/professionals/physician_gls/pdf/thymic.pdf).
52. Jaretski A. Thymectomy for myasthenia gravis: analysis of the controversies regarding technique and results. *Neurology*. 1997;48(suppl 5):S52-S63. doi:10.1212/wnl.48.suppl\_5.S52
53. Klimek-Piotrowska W, Mizia E, Kuzdzal J, Lazar A, Lis M, Pankowski J. Ectopic thymic tissue in the mediastinum: limitations for the operative treatment of myasthenia gravis. *Eur J Cardiothorac Surg*. 2012;42(1):61-65. doi:10.1093/ejcts/ezr268
54. Okuda K, Hattori H, Yokota K, et al. Examination on the necessity of pericardial fat tissue resection in extended thymectomy for myasthenia gravis. *Gland Surg*. 2021;10(8):2438-2444. doi:10.21037/gs-21-318
55. Papadimas E, Tan YK, Luo H, et al. Partial versus complete thymectomy in non-myasthenic patients with thymoma: a systematic review and meta-analysis of clinical outcomes. *Heart Lung Circ*. 2022;31(1):59-68. doi:10.1016/j.hlc.2021.08.003
56. Clark OH. Mediastinal parathyroid tumors. *Arch Surg*. 1988;123(9):1096-1100. doi:10.1001/archsurg.1988.01400330072011
57. Soder SA, Pollock C, Ferraro P, et al. Post-operative outcomes associated with open versus robotic thymectomy: a propensity matched analysis. *Semin Thorac Cardiovasc Surg*. 2023;35(1):189-199. doi:10.1053/j.semtcvs.2021.11.011
58. Burt BM, Nguyen D, Groth SS, et al. Utilization of minimally invasive thymectomy and margin-negative resection for early-stage thymoma. *Ann Thorac Surg*. 2019;108(2):405-411. doi:10.1016/j.athoracsurg.2019.03.010
59. Ackman JB, Verzosa S, Kovach AE, et al. High rate of unnecessary thymectomy and its cause. Can computed tomography distinguish thymoma, lymphoma, thymic hyperplasia, and thymic cysts? *Eur J Radiol*. 2015;84(3):524-533. doi:10.1016/j.ejrad.2014.11.042
60. Inaoka T, Takahashi K, Mineta M, et al. Thymic hyperplasia and thymus gland tumors: differentiation with chemical shift MR imaging. *Radiology*. 2007;243(3):869-876. doi:10.1148/radiol.2433060797